

Validation of the Prostate PRIMARY Score on [¹⁸F] F-PSMA 1007 in High-Risk Prostate Cancer Patients



Filip Markovic^{1,2}, Nabeel Iqbal^{1,2}, Debra Dawson^{1,2}, Abigail Pujols Calero¹, Alisha Moynahan¹, Duncan Sutherland^{1,2}, David Laidley^{1,2}, Jonathan Romsa^{1,2}, Aaron Ward³, Brant Inman^{2,4}, Glenn Bauman^{2,5}, Mina Swiha^{1,2}
¹Department of Molecular Imaging and Theranostics, London Health Sciences Centre · ²Schulich School of Medicine and Dentistry, Western University · ³Robarts Research Institute, Western University · ⁴Department of Radiation Oncology, London Health Sciences Centre · ⁵Department of Urology, London Health Sciences Centre ·

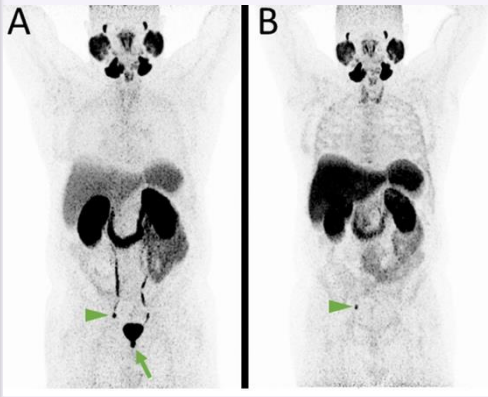
BACKGROUND

Prostate specific membrane antigen positron emission tomography (PSMA PET) imaging has emerged as a critical diagnostic tool in prostate cancer management.

The PRIMARY Score, developed using [⁶⁸Ga] Ga-PSMA-11, combines intraprostatic uptake pattern and intensity for high diagnostic accuracy for clinically significant prostate cancer (csPca).¹

[¹⁸F] F-PSMA-1007 offers advantages including no urinary excretion,² but the PRIMARY Score has not been validated on this radiopharmaceutical.

Purpose:
 Validate the PRIMARY Score on [¹⁸F] F-PSMA-1007 PET/CT in detecting csPca in high-risk patients.



[⁶⁸Ga]Ga-PSMA-11 (A) vs [¹⁸F]F-PSMA-1007 (B)
 Absence of urinary activity [¹⁸F]F-PSMA-1007 improves prostatic fossa demarcation. Arrowheads: concordant lymph node metastasis. Arrow: Urethral/prosthetic fossa uptake visible on [⁶⁸Ga]Ga-PSMA-11 but not visible on [¹⁸F]F-PSMA-1007, not to be confused for local recurrence or additional nodal disease.³

METHODS

Design:
 Retrospective analysis of cohort 0 of the PSMA PET/CT Registry of Recurrent Prostate Cancer (PREP), Ontario.

Population:
 94 men with high-risk PCa at diagnosis (PSA > 20, cT3, and/or International Society of Urological Pathology (ISUP) grade group (GG) ≥ 4 on biopsy, no prior therapy) who underwent [¹⁸F] F-PSMA-1007 PET/CT for staging. ~100 patients expected by final analysis.

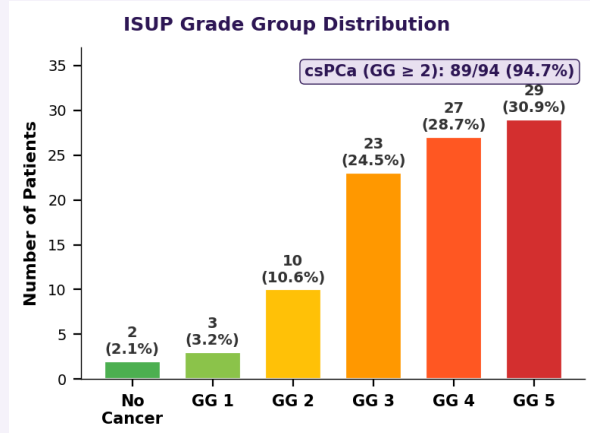
Image review:
 Four nuclear medicine physicians of various training and experience levels independently assign PRIMARY Score; final score by majority read.

Reference standard:
 TRUS-guided biopsy, with secondary correlation to PSA, MRI, and surgical pathology where available.

Variable	Value
Age, median (IQR)	69 (63–75)
PSA ng/mL, median (IQR)	25.8 (17.7–57.8)
PSA > 20 ng/mL	65 (69.1%)
csPca (ISUP GG ≥ 2)	89 (94.7%)
EPE on TRUS biopsy	17 (18.1%)
MRI available	16 (17.0%)
PI-RADS ≥ 4 (of MRI+)	12/16 (75.0%)

Patient demographics and biopsy outcomes. Data represent eligible patients without prior treatment (94 of 110 screened). Cohort characteristics at diagnosis. Eligibility: PSA > 20, cT3, and/or ISUP GG ≥ 4 on biopsy.

RESULTS



ISUP grade group distribution on TRUS biopsy (n = 94). Clinically significant prostate cancer (GG ≥ 2) was present in 89 patients (94.7%), with GG 4–5 comprising 59.6% of the cohort. Five patients (5.3%) had no cancer or GG 1 despite meeting high-risk inclusion criteria (PSA range 22–78 ng/mL); this may reflect TRUS biopsy undersampling of the dominant lesion, underscoring the potential role of PSMA PET-directed biopsy targeting in this population.

CONCLUSIONS
 PRIMARY Score validation on [¹⁸F] F-PSMA-1007 is ongoing. Full results with diagnostic performance metrics will be presented when complete.

Validation of PPS on [¹⁸F] F-PSMA-1007 will provide clinicians with a reliable imaging biomarker for diagnosis and risk stratification of csPca and could play an important role in guiding biopsy.

REFERENCES
 1. Emmett L, et al. J Nucl Med. 2022;63:1644–1650.
 2. Giesel FL, et al. Eur J Nucl Med Mol Imaging. 2017;44:678–688.
 3. Hoberück S, et al. EJNMMI Res. 2021;11:109.

PRIMARY score — Ga-68 PSMA PET
 Visual scoring system for prostate cancer significance

	PRIMARY score	PET / PET-CT (axial)
NON-CLINICALLY SIGNIFICANT Scores 1, 2A, 2B	Score 1 No discernible pattern. Background-level activity only.	
	Score 2 — Pattern A Diffuse transition zone uptake. Spares the peripheral prostate margin. Intensity may vary.	
	Score 2 — Pattern B Central zone activity, often symmetrical. Becomes Score 4 if it reaches the peripheral margin.	
CLINICALLY SIGNIFICANT Scores 3, 4, 5	Score 3 — Pattern C Focal transition zone activity. At least twice background TZ uptake on visual inspection.	
	Score 4 — Pattern D Focal peripheral zone activity. Any focal uptake at the prostate margin or apex (no minimum SUV).	
	Score 5 Intense uptake with SUVmax greater than 12, irrespective of zonal location or pattern. Overrides all other patterns.	

Schematic axial pelvis: bladder (top), prostate (centre), femoral heads (sides). SUV scale fixed to a maximum of 8 for all panels. Light blue = low background activity; warmer colours indicate progressively higher PSMA uptake intensity.

